Utilizing implant-retained auricular gold bars for unusual patient-requested custom appliances to enhance lifestyles

David Morrison* HND, Ann McLaren ABFA, Nick Blanas BSc DDS FRCD(C), Eszter Somogyi-Ganss, DMD, MSc Pros, PhD, FRCD(C)

Craniofacial Prosthetic Unit, Department of Dental and Maxillofacial Sciences
Sunnybrook Health Sciences Centre
Toronto, ON, Canada

The 68th Annual Meeting of the AMERICAN ACADEMY OF MAXILLOFACIAL PROSTHETICS

Sunnybrook HEALTH SCIENCES CENTRE

Introduction

Implant –retained prostheses offer the gold standard of prosthetic rehabilitation for patients who require an auricular prosthesis (1). Clinical quality of life assessments also demonstrate evidence that the patients receive not only a physical benefit to their prosthesis but a psychological one as well (2,3).

As patients adapt to prosthetic rehabilitation and the new activities that their prostheses afford them, a few auricular patients have returned to the Craniofacial Prosthetic Unit (CPU) at the Sunnybrook Health Sciences Centre to request other custom appliances that utilize their actual prosthesis or auricular gold bars to further enhance their psychological well-being or lifestyle.
Three very different examples of these requests are covered in this poster.

Figure 1. Patient A. with implant-retained auricular prosthesis (left) and with an implant-retained hearing aid holder (right)

Prosthesis 1: The Sleep Aid

Patient A. had previously received an implant-retained auricular prosthesis and the result was excellent (Figure 1). The patient had been satisfied in every aspect and had initially left very happy. However, he returned to the unit a few weeks later looking very tired, visibly anxious and stressed. This was, he said, due to the weeks of insomnia he had experienced as he reported that at bedtime, the contact of his pillowcase against his gold bar generated a roaring sound that was transmitted via his gold bar, which was acting like a bone-conduction device. He was in a state of desperation and needing something to be done to resolve the nighttime noise and restore his sleep and neurological state.
A substructure was created over 3 gold clips in the same way as his regular prosthesis. A custom mould was then made to enable a 4mm thickness of 2186 silicone (Factor II, Lakeside, AZ, USA) to be bonded over it. Plenty of space was left between the underlying skin and the device so as to enable the skin tissue to breathe (Figure 2).
This device had the immediate result by successfully dampening the sound of the pillowcase and restored the patient's ability to sleep restfully once more, restoring his quality of life. He was in a state of desperation and needing something to be done to resolve the nighttime noise and restore his sleep and neurological state.

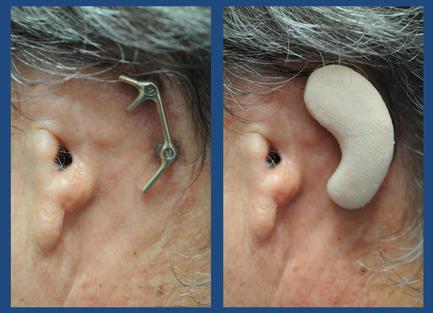

Figure 2. Gold implant bar (left) and implant-retained sleep aid (right)

Prosthesis 2. The Hearing Aid

Patient A. again returned for a regular appointment many years later. He had since retired and requested if a different auxiliary prosthesis could be made to assist his current health situation; namely that he was wearing an over-the-ear hearing aid that fits behind the pinna of his prosthesis.
Patient A. reported that he did not always like to wear his prosthesis on certain days when he was alone but he still needed the hearing aid. He had been attaching his hearing aid directly to the gold bar with an elastic band but he sought a more practical solution.
A dummy hearing aid was obtained from the patient's hearing aid clinic along with technical guidance on the location of microphones, charging ports and battery cover; so as to leave these areas clear. Magnetic retention for the custom device was not an option as the hearing aid housed a strong magnet and would damage the internal mechanisms. Another substructure was made and a "bucket" built over it using Orthoresin (Dentsply, Hanau-Wolfgang, Germany, EU). To prevent the hearing aid from inadvertently spilling out during chores, a rubber O-ring of suitable size was obtained to grip the hearing aid and incorporated into the acrylic resin. It was snug enough to rest in the acrylic but could be retrieved along with the hearing aid device when required (Figure 3.).

Figure 3. Hearing aid fastened to the gold bar by the patient (left) and implant-retained hearing aid holder (right)

Prosthesis 3. The Ear Bud

Patient B. had recently received his first prosthesis and he had been really pleased with the successful result. His main motivation in wanting a prosthesis had been to boost his confidence in seeking employment in a healthcare setting.
However, he reported that he had since become very self-conscious when his colleagues unexpectedly engaged him in conversation on his non-hearing right side. The prosthesis was, he felt, so completely lifelike that his colleagues could not perceive why he might not respond and he felt that his ignorance was being misinterpreted as rudeness.
The patient proposed that his lack of response could be excused as ignorance if people could see a music ear bud. However, his ear store-purchased ear buds did not fit his silicone prosthesis well and he requested if something could be done to make one fit.
The patient provided an ear bud and a custom mould was made of it (Mould Star 16 Fast. Smooth-On, Macungie, PA, USA). It was cast in Smooth-Cast 305 (Smooth-On, Macungie, PA, USA) white epoxy resin and resin used again to fit it to the concha of a simple silicone casting of his prosthesis from the patient's mould. A regular stainless steel screw of flush size was drilled into the end so that the dummy ear bud had a metallic appearance for visual effect and the iconic black lines were added with Tamiya lacquer paint (Tamiya America Inc., Irvine, CA, USA) (Figure 4.).
An economy pair of ear buds were also purchased and the right one was set directly into the prosthesis, again using Smooth-Cast 300 (Smooth-On, Macungie, PA, USA) white epoxy resin and polished (Figure 4.).

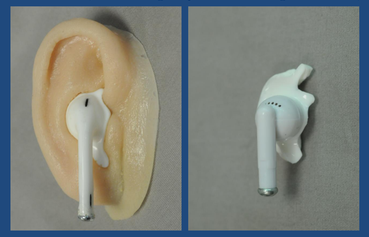

Figure 4. Fabricated ear bud in relation to the prosthesis (left) and abricated ear bud (right)

Conclusion

Some patients with auricular implant-retained prostheses may require an extra auxiliary device to enhance their lifestyles or well-being by utilizing the existing gold bar to facilitate this. With the array of dental and laboratory materials at hand to an anaplastologist, these can be successfully made to further the prosthetic rehabilitation of these patients.

References

1. Maxillofacial prosthetic rehabilitation: A survey on the quality of life *J Pros Dent* 2018 Nov;120(5):780-786.
2. Long-term quality of life assessment in patients with auricular prostheses *Craniofac Surg*. 2013 Mar;24(2):392-7.
3. Prosthesis auricular with osseointegrated implants and quality of life. *J Craniofac Surg*. 2010 Jan;21(1):94-6.

Contact:
David Morrison HND
david.morrison@sunnybrook.ca